PART 4 | Trauma

CHAPTER

31 Maxillofacial trauma

Learning objectives

- To understand and identify potentially life-threatening injuries to the face, head and neck
- To safely perform a systematic examination of facial injuries, and describe the basic classification of soft-tissue and bony injuries
- To describe the principles of management of facial soft-tissue injuries
- To understand and describe the principles of management of fractures of various facial bones, and appreciate the initial management of dental injuries

EMERGENCY ASSESSMENT AND MANAGEMENT

Maxillofacial injuries that require hospital attendance are common and are most frequently related to trips and falls, road traffic accidents (RTAs), taking part in sports and interpersonal violence. Initial assessment requires a focused history of the mechanism of injury and a general medical and social history, followed by clinical examination. An injury to the body including facial trauma must be managed with an immediate assessment of the airway, breathing and circulation (ABC) in line with the established Advanced Trauma Life Support (ATLS) guidelines. Any visible object obstructing the airway should be removed if possible, and, if indicated, direct pressure should be applied to bleeding points. If the patient has midface bleeding where direct pressure cannot be applied, the conscious patient may sit forwards or be placed on their side in the standard recovery position to minimise the risk of blood obstructing the airway. Care should be exercised if there are concerns of concurrent spinal injury.

In severe injury to the midface skeleton, the maxilla can become detached from the skull base and displaced downwards and backwards (***Figure 31.1***). The patient may present with acute airway compromise if the midface impaction is also combined with a bilateral mandibular fracture, which can displace the tongue backwards. Such injuries are often associated with significant oedema of the soft palate and tongue (***Figure 31.2***). In these situations, the team must be prepared to undertake an endotracheal intubation, a needle cricothyroidotomy or an emergency surgical airway procedure if intubation proves difficult. There are certain techniques that can be used immediately to relieve airway compromise, while preparations are made for definitive airway management. In the obtunded or unconscious patient, the maxilla can be disimpacted and pulled forwards using fingers. The tongue can be pulled and held forwards, with a large suture or a towel clip, to help open up the airway. High-volume suction must be readily available to clear the blood as well as tooth fragments and debris from the oral cavity and upper aerodigestive tract.

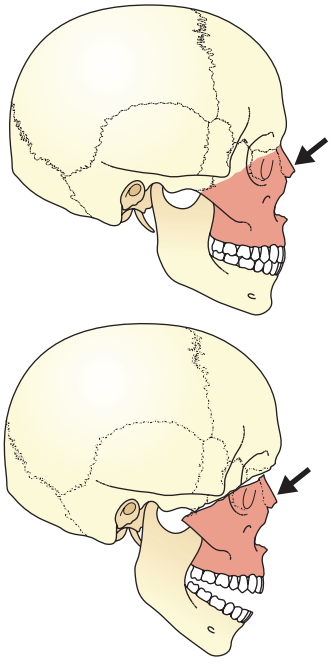

Figure 31.1 A severe blow to the midface may detach the facial skeleton from the base of the skull and push it downwards and backwards.

Torrential life-threatening haemorrhage may be seen in facial trauma that involves large soft-tissue lacerations, penetrating neck injuries or ballistic injuries. The source of such bleeding is likely to be from injury to the maxillary artery or pterygoid venous plexus in the grossly damaged midface, or branches of the external carotid artery or tributaries of the internal jugular vein in penetrating injuries of the neck. The management of severe bleeding may require application of

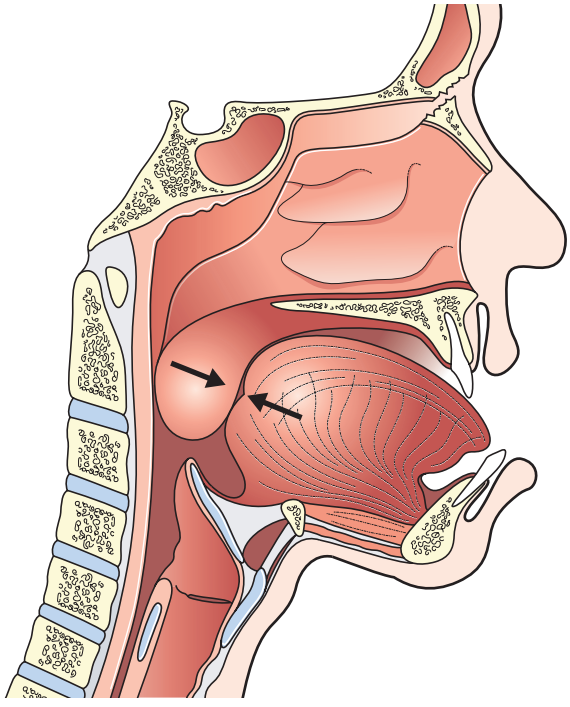

Figure 31.2 Loss of pharyngeal space secondary to oedema of the soft palate and the posteriorly displaced tongue may restrict the airway.

direct digital pressure or placement of anterior and posterior nasal packs. Specific inflatable balloon nasal packs or Foley urinary catheters may be utilised to exert pressure on the bleeding points. An endotracheal intubation or a surgical airway may be required if there is concern regarding extensive soft-tissue swelling secondary to injury or surgical intervention (*Figure 31.3*).

It is important to assess the maxillofacial patient for severe head injury that can result in significant cerebral damage. Patients with facial injury and particularly those with injury due to interpersonal violence are frequently intoxicated because of alcohol or drug abuse, which may mask the symptoms of head injury. Therefore, clinicians should have a low threshold for requesting a brain computed tomography (CT) scan to exclude significant intracranial injury. In such cases, it is prudent to include the facial bones in the CT request if indicated. Injuries to the midface are frequently associated with orbital damage, which can lead to loss of sight if not dealt with urgently. Retrobulbar haemorrhage, which can cause acute compression of the optic nerve if not treated immediately, may lead to loss of vision (see *Orbital fractures*).

Summary box 31.1

Emergency assessment and management

- Immediate management must include assessment of ABC with cervical spine protection, following which a more detailed assessment should ensue
- Life- and sight-threatening facial injuries should be treated immediately
- The clinical team should be prepared for endotracheal intubation or, if required, a surgical airway

CLASSIFICATION OF FACIAL INJURIES

Bony injury

Maxillofacial bone fractures can be divided into several types: simple (isolated single), compound (communicates through the skin or oral/nasal mucosal surfaces), comminuted (multiple fragments), complicated (with neurological or vascular injury), greenstick (includes single cortex) and pathological (through an existing lesion such as neoplastic or inflammatory). Fractures can be further classified into undisplaced, minimally displaced or displaced.

The facial skeleton can be divided vertically into thirds using horizontal lines: upper face (from the level of the canthi upwards), midface (from the maxillary teeth to the canthi) and lower face (mandible and mandibular teeth). The midface can be further divided into central and lateral, with the naso-orbital–ethmoidal complex forming the central and the zygomaticomaxillary complex forming the lateral components. Orbital (eye socket) fractures can occur in isolation or in combination with other fractures. Orbital fractures can be classified into orbital floor, medial and/or lateral walls and the roof of the orbit.

Figure 31.3 Tracheostomy *in situ* perioperatively to protect the airway in a patient with extensive facial fractures secondary to a road traffic accident.

Frederic Eugene Basil Foley, 1891–1966, urologist, Ancker Hospital, St Paul, MN, USA.

Skull fractures including frontal and ethmoidal sinuses, in combination with facial fractures, are termed craniofacial fractures. A joint neurosurgical and maxillofacial approach is necessary in these cases because of the possibility of intracranial injury. Frontal sinus fractures are classified into those involving the anterior or posterior table, with or without damage to the frontonasal duct.

The most severe facial fractures involving bony injury at all levels of the facial skeleton are referred to as panfacial fractures. These usually imply that a significant degree of force has been involved, suggesting significant other injuries such as head, abdominal or chest injuries.

Soft-tissue injury

Lacerations are a result of crushing injuries where the soft tissues are compressed onto the underlying bone, usually by a blunt object. Sharp implements, such as a knife or glass, cause incised wounds. Any soft-tissue injury can present with or without tissue loss. Where the injury results in a communication between the skin and the mucosa of the oral or nasal cavity, the wound is termed 'through and through'. The soft-tissue injury may present with or without damage to the underlying bony structure.

Summary box 31.2

Classification of facial injuries

- There are multiple ways of classifying facial fractures, the simplest way is to divide the face into thirds and describe the specific bone involved
- Assess orbit independently
- Assess soft-tissue injury in terms of loss of tissue and damage to the underlying bone

CLINICAL ASSESSMENT

History

The history should include the mechanism of injury, past medical history and the postinjury events; it should be obtained directly from the patient and from witnesses and the first responding emergency services if required. Knowledge of the mechanism of injury will often help to identify potential occult injuries that may not be readily detectable on first inspection. Factors such as sharp or blunt trauma, wound contamination and energy transfer should be assessed and recorded. The medical history should gain information to indicate the general fitness of the patient for potential treatment under general anaesthesia. It is important to obtain previous tetanus vaccination history, and the vaccine should be given promptly if there is a high risk of contamination.

Examination

Primary survey

The primary survey is aimed at protection of the airway, control of bleeding, restoration and maintenance of the circulation and assessment for neurological deficits, including the Glasgow Coma Scale (GCS) score, with cervical spine control.

The head and neck region should be inspected, with wounds assessed for skin or soft-tissue loss and subsequently dressed appropriately to control any bleeding. The wound size, location and depth should be carefully recorded. Large and obvious foreign bodies should be removed but care should be exercised with penetrating wounds involving large fragments or blades, which can potentially penetrate important deep structures. These should be removed in the operating theatre, under more controlled conditions, after appropriate imaging.

Secondary survey

The secondary survey examination should be conducted in a systematic way, preferably following a top-down approach carefully examining all structures, recording obvious as well as less conspicuous injuries. The surface inspection should include the scalp, posterior neck and ears and then move to the frontal view. A brief cranial nerve examination should be undertaken as guided by the injury site. Particular attention must be paid to cervical spine examination as the patient with facial injury may have concurrent spinal injury, which may have been missed in the primary assessment.

Examination of the eyes should include visualisation of the periorbital tissues and assessment of globe position, visual acuity, diplopia (double vision), intercanthal distance and eye motility. This examination may be difficult if the eyelids are swollen and the eyes are shut. However, such an examination is crucial as inadequate examination may lead to a delay in the diagnosis of serious eye injury that may need urgent intervention to prevent blindness. Examination is possible even in the most swollen of eyes by gently pulling the eyelids apart with dry gauze, a cotton bud/roll or a microbiology swab stick. Gentle pressure on the eyelid for a brief period may reduce oedema, which may facilitate the opening of the eyelids. It may be helpful to ask a colleague to perform the eye examination if one is holding the eyelids apart to facilitate examination.

The facial bones should be palpated for signs of fractures, which may include step deformity, tenderness or bony asymmetry. A systematic approach would include palpation of the supraorbital ridge followed by the lateral orbital wall, inferior orbital rim, zygomatic bone, nasal bones, temporomandibular joint and the rest of the mandible on both sides.

The examination of the oral cavity should include inspection for any soft-tissue lacerations, bruising, haematoma, injury to dentition and assessment of occlusion (bite). Any blood and excessive secretions should be suctioned and a good light source used to facilitate thorough examination. The teeth should be examined and their presence or absence noted. Teeth may be knocked out completely (avulsed), displaced but still attached to soft tissues and/or bone (luxated) or fractured. It is important to account for all missing teeth or tooth fragments as aspiration is a major risk for developing chest infection. If it is unclear about the location of missing teeth, a chest radiograph should be considered.

A key feature of displaced mandibular or maxillary fractures is altered occlusion. The patient may be able to detect even a tiny alteration in their occlusion. If there is a fracture of the mandible, the overlying mucosa is often torn and there

Figure 31.4 Left parasymphyseal fracture of the mandible demonstrating a step deformity that could be confused with a missing tooth in inexperienced eyes.

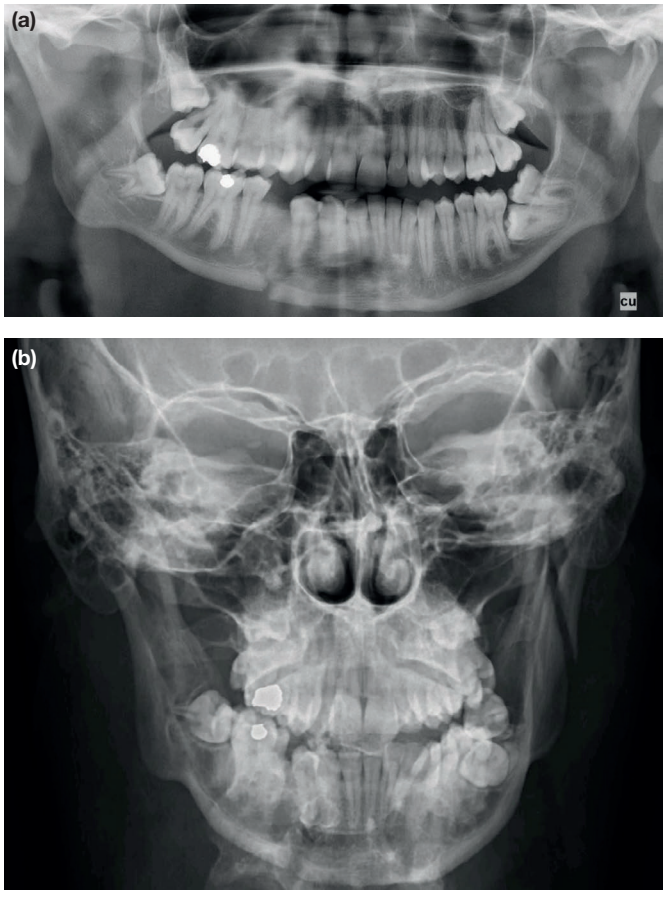

Figure 31.5 (a) Orthopantomogram (OPT) demonstrating a right mandibular body and left condylar fracture. **(b)** A posteroanterior mandible radiograph reveals the left low condylar fracture more clearly, which may not be as obvious as in the OPT to an inexperienced clinician.

may be an associated haematoma in the floor of the mouth (*Figure 31.4*). If the mandibular fracture is grossly displaced, the patient may have altered sensation in the region of the lip and chin, due to damage to the inferior alveolar nerve running along the canal within the mandible and involvement of the mental nerve, a sensory branch, which emerges from the mental foramen.

Figure 31.6 Occipitomental radiograph demonstrating a right zygomatic fracture. Note the right maxillary sinus opacification, which is one of the radiological hallmarks of zygomatic fracture due to collection of fluid in the sinus.

Investigations

The nature of the injury sustained will determine the specific investigations required to facilitate diagnosis. Systemic investigations may include routine haematology and biochemistry investigations, and imaging requests such as cervical spine, chest, abdominal or limb radiographs depending on the site of injury.

If a mandibular fracture is suspected, an orthopantomogram (OPT) and a posteroanterior (PA) radiograph of the mandible should be obtained (*Figure 31.5*). It is extremely important to have two views at right angles to each other to avoid missing any fractures. Very occasionally a lateral mandibular view may have to be utilised as a screening radiograph if the patient is unable to cooperate for the OPT (e.g. patients with dementia). For a suspected midface fracture, occipitomental (OM) radiographs at 10° and 30° should be obtained (*Figure 31.6*). A CT of the facial bones would be more suitable if an orbital fracture is suspected or in the case of a high-impact injury; this will provide the gold standard detail of bony structures and, as previously mentioned, should include the brain if there is any suggestion of a head injury. A three-dimensional (3D) reformatting of the CT scan allows for excellent visualisation of the maxillofacial bony structures.

Summary box 31.3

History, examination and investigation

- A detailed history of the mechanism of injury is crucial in any initial assessment
- A systematic approach should be adopted in examination of the craniomaxillofacial structures; a top-down approach is recommended
- The most common radiographs requested in facial fracture investigation are OPT and PA mandible for mandibular fractures, and OM facial views for midface fractures

SPECIFIC INJURIES

Soft-tissue injuries

Lacerations

Soft-tissue injuries of the face are a result of blunt or sharp trauma and should be carefully examined to exclude any associated nerve, parotid duct or underlying bony injury (*Figure 31.7*). These can mostly be repaired under local anaesthesia (LA) and should be treated within 24 hours of injury to avoid poor healing and an unsightly scar. Lacerations in uncooperative children and large contaminated wounds in adults usually require repair under general anaesthesia (GA). Uncomplicated wounds with no tissue loss should be cleaned and closed in layers. If the skin is contaminated with dirt, it should be gently scrubbed with a soft brush to prevent dirt tattoo. Facial skin has a rich blood supply, which contributes to its excellent healing; therefore, wounds should only be debrided of frankly necrotic tissue.

Intraoral wounds heal very well; if small, they can be left to heal by secondary intention, especially in children to avoid treatment under GA. Resorbable 3-0 or 4-0 sutures are placed intraorally and for the deep layers of the skin. The most superficial skin layer should be closed with a 5-0 non-resorbable monofilament suture, except in potentially uncooperative children when 5-0 or 6-0 resorbable sutures can be used. Some surgeons also use resorbable 5-0 or 6-0 skin sutures in adults. For some small superficial clean incised wounds, cyanoacrylate tissue glue can be utilised. This must be avoided in periocular skin because of the risk of spillage into the eye, which can lead to severe corneal damage.

Lacerations involving the eyelid margins and those crossing the vermilion border of the lip need special attention to avoid poor approximation of the skin edges, which can result in a poor cosmetic outcome. If there is tissue loss, adjacent skin can be undermined and mobilised to achieve primary closure, but incisions for local flaps or skin grafts should be avoided in the initial management. Very large areas of tissue loss may require free flap reconstruction if local tissue flaps are inadequate for resurfacing the defect.

Facial nerve

Facial nerve function should be routinely assessed in all facial lacerations. Any nerve injuries are best repaired primarily under high magnification and GA. In general, nerve injuries that lie lateral to the line drawn vertically down from lateral canthus of the eye are repairable, and this should be attempted. A nerve stimulator or monitor may be helpful in identifying the transected nerve ends.

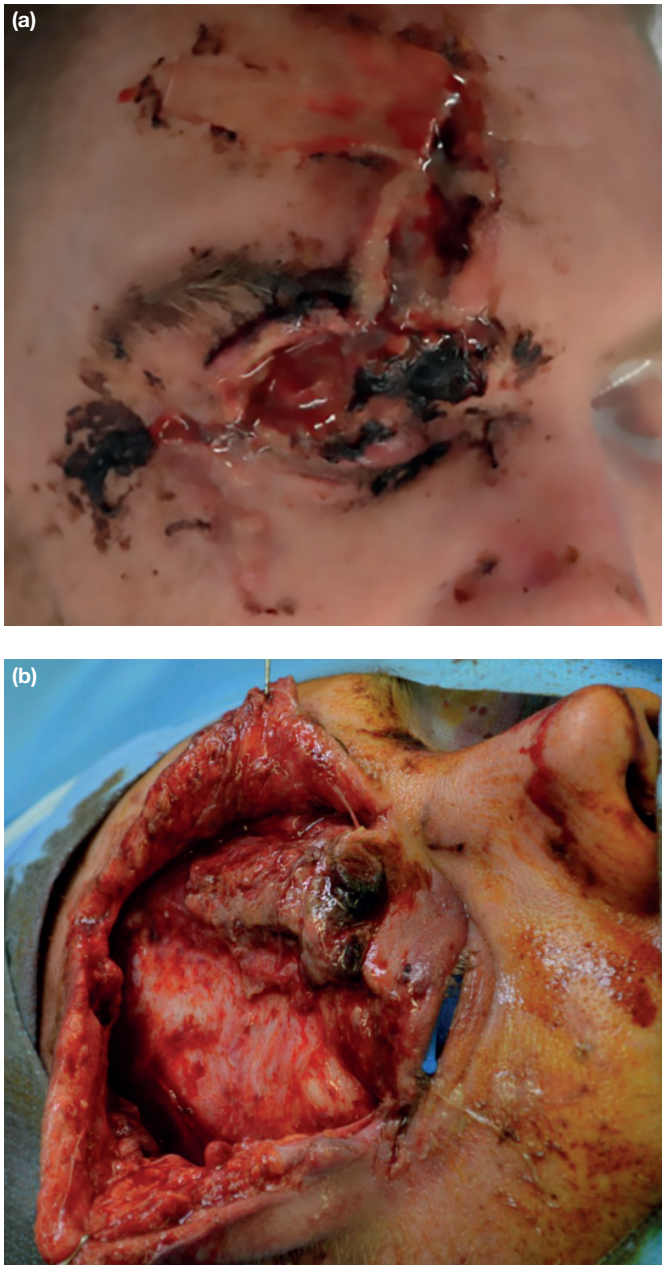

Figure 31.7 (a, b) Extensive soft-tissue laceration, the full extent of which may only be revealed on careful examination. Corneal protection *in situ*.

Parotid duct

The middle third of a line drawn from the tragus of the ear to the midpoint between the upper lip and the alar base represents the surface landmarking of the parotid duct. A careful examination of the wound may reveal saliva leak in the case of a duct injury. Methylene blue solution can be injected through the parotid duct opening intraorally (adjacent to the

upper molar teeth) and any leak assessed in the wound bed. The repair is best achieved under high magnification, over a cannula inserted through the duct opening under GA. The buccal branch of the facial nerve that closely follows the duct may also get transected in the injury; this requires careful examination.

Animal and human bites

Facial bites should be cleaned thoroughly and closed primarily in layers. Because of the high risk of wound infection, antibiotics must be prescribed according to local microbiology guidelines. With human bites, consideration should be given to testing the patient for human immunodeficiency virus (HIV) infection, and hepatitis serology is also sensible, if the patient is deemed to be at high risk of being infected as a result of the bite. If there is significant tissue loss, a staged reconstruction may be required.

Summary box 31.4

Soft-tissue injuries

- Examination of the function of both motor and sensory nerves should be conducted prior to the administration of LA
- All animal and human bites must be covered with prophylactic antibiotics
- Tissue loss may require staged reconstruction

Mandibular fractures

Fractures of the mandible are common in the context of facial injury and may frequently involve multiple sites. The commonest fracture patterns are parasymphysis and angle fractures, or parasymphysis and condylar fractures (contralateral sites in both cases). The specific sites in the mandible most prone to fractures are shown in ***Figure 31.8***. It is very important to record the presence or absence of any paraesthesia in the region of the lower lip and chin, which may be the result of damage to the inferior alveolar nerve.

Most displaced mandibular fractures are treated with antibiotics on admission followed by open reduction and internal fixation (ORIF). Typically, titanium miniplates and screws are placed (***Figure 31.9***) under GA with two or three postoperative intravenous antibiotic doses given. Undisplaced fractures may be treated conservatively; this may include antibiotics, analgesia and a soft diet for 4 weeks. These patients need to be monitored closely to exclude failure of conservative management, which will commonly be indicated by increasing pain and a change in occlusion. In general, facial bones heal well after about 4 weeks. Occasionally, if the fractures are severely comminuted and difficult to fix with titanium plates, intermaxillary fixation (IMF) with wires can be considered; however, this is becoming exceedingly rare owing to the advances in osteosynthesis fixation techniques.

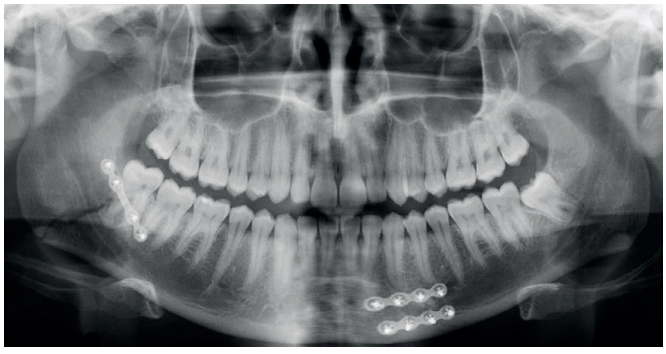

Figure 31.9 Postoperative orthopantomogram demonstrating fixation of a right angle and left parasymphyseal fracture with miniplates and screws.

Simple mandibular fractures treated with the ORIF technique should have two 2-mm-diameter screws on either side of the fracture, engaging a single bone cortex (monocortical). These small plates are load sharing, which indicates that the fractures are reduced and load is shared between the bone and the plate. With more complex or comminuted fractures, heavy profile reconstruction plates and bicortical screws may be placed as a load-bearing fixation technique. In general, different mandibular sites determine the number of miniplates used; for example, a single plate is placed along the line of maximal tension for angle and body of mandible fractures, while two plates are placed 5 mm apart for parasymphyseal fractures to resist the torsional forces of the anterior mandible musculature. A transbuccal approach through a tiny incision in the cheek skin is frequently utilised for angle fractures to allow placement of screws perpendicular to the plate and the bone.

Most condylar fractures can be treated with closed reduction with IMF elastic guidance and a strict soft diet and analgesic regimen. However, displaced condylar neck fractures with significant loss of mandibular height are increasingly treated with ORIF techniques. Various approaches can be adopted depending on the condylar fracture location, although the most common approach is transparotid access with a retromandibular incision. There have been some advances towards endoscopic-assisted fixation of the condylar fractures in some maxillofacial units.

The optimal timing for the repair of a mandibular fracture is within 24–48 hours post injury. For a heavily displaced fracture where there is likely to be delay in taking the patient to theatre, a bridal wire that goes around the teeth to temporarily reduce the fractures may be useful in alleviating pain and facilitating oral intake.

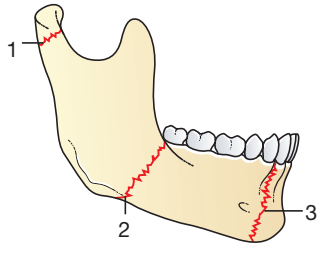

Figure 31.8 Fractures of the mandible. (1) The neck of the condyle is the most common site, followed by (2) the angle of the mandible. (3) The third point of weakness is in the region of the mental foramen.

Summary box 31.5

Mandibular fractures

- Always look for a second mandibular fracture as contralateral fractures are common
- It is important to record the presence or absence of paraesthesia in the distribution of the mental nerve
- Most mandibular fractures are treated with ORIF using titanium miniplates and screw fixation, ideally within 24–48 hours of injury

Zygomatic fractures

Zygomatic (cheek/malar) bone fractures are often the result of blunt trauma to the midface, such as from a fist. From a clinical perspective, it is helpful to consider the zygomatic bone as a four-legged stool, as shown in ***Figure 31.10***. The four legs comprise the zygomatic arch running anteroposteriorly, the zygomatic process running vertically to join the fronto-zygomatic (FZ) process of the frontal bone at the FZ suture, the infraorbital rim running horizontally and the maxillary buttress running vertically. Zygomatic fractures may include isolated or multiple fracture lines involving any of these legs, often in combination with orbital wall fracture.

Zygomatic fractures may be difficult to assess in the presence of significant facial swelling; therefore, patients are usually reviewed in clinic 1 week after injury to allow the swelling to subside. There may be periorbital swelling and bruising, step deformity and frequently a subconjunctival haemorrhage with no posterior border or limit (***Figure 31.11***). A concomitant orbital bone fracture also needs to be excluded; if suspected, a CT scan to include the orbits should be obtained.

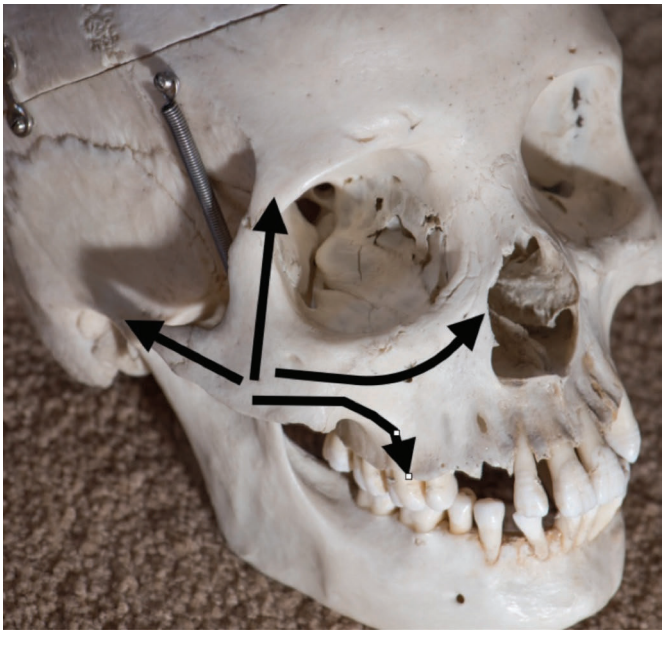

Figure 31.10 The 'four legs of the stool'.

Figure 31.11 Fractures of the zygoma may often be associated with periorbital swelling and subconjunctival haemorrhage without a posterior border or limit.

Undisplaced or minimally displaced zygomatic fractures are often treated conservatively, with patients being told to avoid any excessive pressure on the affected side for a minimum of 3 weeks. The indications for surgical intervention include asymmetrical cheek bone prominence, persistent eye symptoms such as diplopia, orbital deformity and restricted mouth opening due to impingement of the coronoid process by the bone fragment.

There are a variety of transcutaneous (including upper and lower lid) and intraoral surgical approaches for access, determined by the exact location of the fracture. The isolated zygomatic fracture is often reduced by a closed technique involving an incision in the temple (Gillies' lift) or intraorally (Keen's technique). The ORIF of FZ suture fractures and infraorbital rim or maxillary buttress fractures usually includes low-profile 1.5-mm midface titanium plates and screws. The provision for single-, double-, triple- or four-point fixation of the zygomatic fracture is dependent on the stability of the fracture post reduction and the degree of bone comminution.

Summary box 31.6

Fractures of the zygomatic bone

- Fractures of the zygomatic bone often require follow-up 1 week after the injury for the swelling to subside to allow full assessment
- Orbital fractures may occur in combination with zygomatic fractures
- There are a variety of transcutaneous or intraoral surgical approaches that are determined by the exact location of the fracture

Sir Harold Delf Gillies, 1882–1960, born New Zealand, studied medicine at the University of Cambridge, Cambridge, UK, pioneer of plastic surgical techniques during and after the First World War.
William Williams Keen, 1837–1932, pioneer American neurological surgeon.

Maxillary bone fractures

Maxillary fractures are classified according to their anatomical level, as originally described by René Le Fort (*Figure 31.12*). Le Fort I involves a fracture line extending from the pterygoid plates through the lateral wall of the maxillary sinus and piriform aperture of the nose. Le Fort II involves the whole of the dentition-bearing portion of the maxilla and the nasal bones. The fracture line extends from the pterygoid plates to the inferior orbital rim and across the bridge of the nose. Le Fort III fracture essentially is where the whole of the midface is separated from the skull base. The fracture line runs from the pterygoid plates to the base of the zygomatic arch, the lateral walls of the orbit through the FZ suture and the nasal bridge.

The Le Fort classification is simple to describe, but the clinical presentation may not be as clear-cut as the fractures at these levels rarely occur in isolation. There may be significant commination owing to the thin composition of the maxillary bone as well as the differing pattern of fracture on two sides.

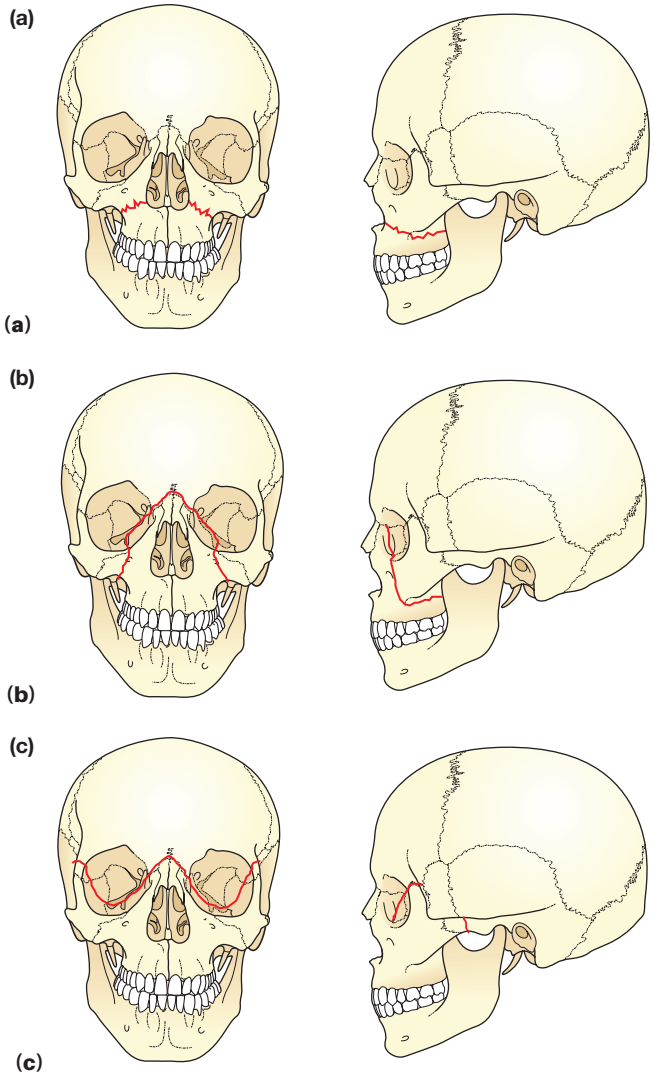

Figure 31.12 Maxillary fractures as classified by Le Fort. **(a)** Le Fort I; **(b)** Le Fort II; **(c)** Le Fort III.

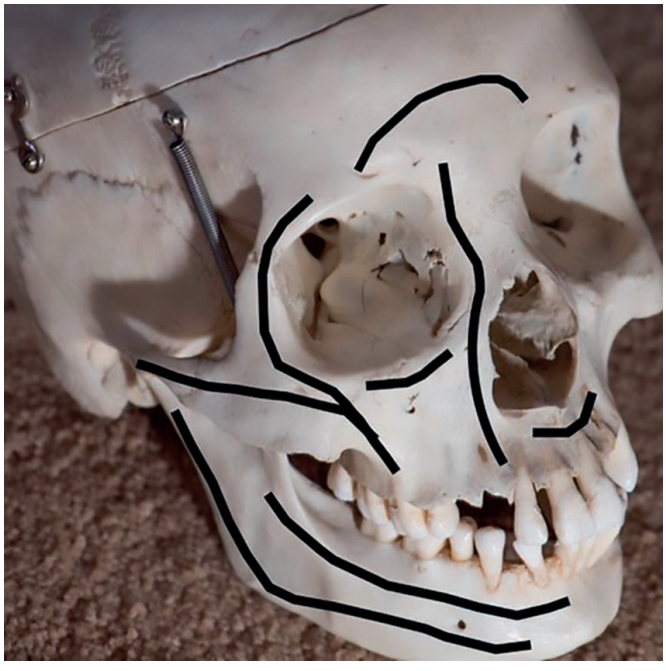

Figure 31.13 The buttresses of the facial bones. These are the strongest part of the facial skeleton and may help with fixation because of good bone quality.

Undisplaced or minimally displaced factures are best treated conservatively with a soft diet and analgesia. The indications for ORIF include a mobile, unstable maxilla, deranged occlusion such as an anterior open bite and loss of facial projection and width resulting in obvious facial deformity. Fixation is achieved with midface 1.5-mm miniplates and screws, with various surgical approaches for access depending on the location of the fracture. Plates are usually placed along the main facial buttresses, which provide the optimal strength and bone quality to be able to hold the screws (*Figure 31.13*).

Summary box 31.7

Maxillary bone fractures

- Maxillary fractures occur at various levels, which may not follow the typically described Le Fort classification pattern owing to comminution and asymmetry of the fracture
- Maxillary fractures may be associated with significant bleeding (often from the pterygoid plexus), which may require packing of the nasal cavity

Orbital fractures

Orbital fractures may be isolated or more commonly occur in conjunction with zygomatic or maxillary complex fractures. They most frequently involve the orbital floor, followed by the medial wall, lateral wall or the roof, which may present in

René Le Fort, 1869–1951, French surgeon, classified facial fractures after macabre research in which he dropped rocks and other heavy objects onto the faces of cadavers.

Figure 31.14 Coronal computed tomography (CT) scan demonstrating a left orbital blow-out fracture, with soft-tissue herniation into the maxillary antrum.

combination or as isolated injuries. Isolated orbital injuries are described as 'blow-out' or 'blow-in' fractures. An example of a blow-out fracture is shown in ***Figure 31.14***.

Orbital floor fractures may lead to restricted upward gaze owing to trapping of orbital fat and fibrous septae resulting in diplopia on looking upwards. Occasionally, the inferior rectus or inferior oblique muscles may also be trapped. Inferior rectus muscle entrapment in children may present as the oculocardiac reflex: a triad of bradycardia, nausea and syncope. This needs to be treated as an emergency because irreversible damage related to muscle necrosis can occur within hours. In these cases, on imaging, the orbital floor may appear undisplaced or minimally displaced, which means that a trapdoor defect has opened and then closed again, entrapping the muscle. They are also described as a 'white eye' blow-out fracture as children often present with no subconjunctival haemorrhage (***Figure 31.15***). In addition to the restricted eye movement, orbital wall fractures can lead to changes in globe position, with inferior positioning of the globe (hypoglobus) or sinking in of the globe due to an increase in orbital volume (enophthalmos). These globe position changes may only become visible after the initial swelling has subsided; the true extent is only revealed 2–4 weeks after the injury.

The indications for surgical repair of orbital fractures include enophthalmos or persistent diplopia resulting from restricted eye motility as a result of extraocular muscle entrapment within the fracture line. It is important to seek orthoptic assessment; this is helpful in differentiating between muscle entrapment and muscle dysfunction (secondary to inflammation), both of which may cause diplopia. Diplopia secondary to muscle dysfunction is likely to resolve spontaneously with time. Repair of the orbital rim is usually accomplished with ORIF techniques and the orbital walls repaired with preformed or patient-specific titanium implants or less commonly autologous materials such as cranial bone grafts.

Figure 31.15 This 11-year-old boy presented with an oculocardiac reflex secondary to a 'white eye' blow-out left orbital floor fracture following a rugby injury.

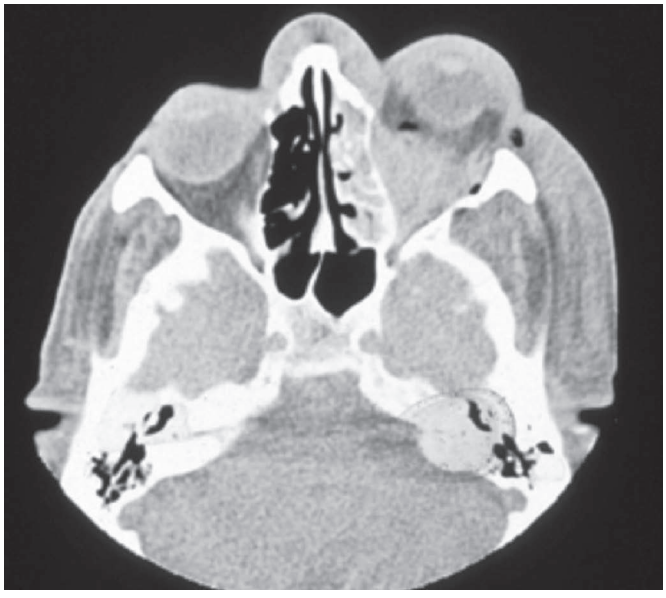

Figure 31.16 An axial CT scan demonstrating left retrobulbar haemorrhage and severe proptosis. This should be a clinical diagnosis and treated immediately, rather than as a finding on the CT scan later.

A retrobulbar haemorrhage is an acute surgical emergency as it can lead to blindness secondary to pressure-induced reduced flow on the retinal artery, leading to ischaemic damage to the optic nerve (***Figure 31.16***). It presents with tense proptosis, increasing pain, reduced visual acuity and loss of the pupillary response. One of the early signs may be altered perception of red colour in the affected eye. If this is suspected, preparation should be made for immediate bedside lateral canthotomy and cantholysis under LA to allow the globe to bulge forwards and relieve the pressure posteriorly. Concomitant medical management should also be initiated with mannitol, acetazolamide and steroids.

Summary box 31.8

Orbital fractures

- Orbital fractures may be isolated or in combination with zygomatic or maxillary fractures
- Children may present with a trapdoor orbital floor fracture that may cause an oculocardiac reflex, requiring urgent surgical intervention to prevent muscle necrosis
- Retrobulbar haemorrhage is a surgical emergency treated with bedside lateral canthotomy and cantholysis under LA to prevent blindness

Frontal sinus fractures

As frontal sinus fracture signifies a large amount of force applied to the cranium, any concomitant intracranial injuries must also be identified and treated appropriately. Frontal sinus fracture may be classified according to whether the anterior, posterior or both tables are involved with or without fracture of the sinus floor, which raises concern for possible injury to the nasofrontal duct (*Figure 31.17*). If combined with a dural tear, there may be cerebrospinal fluid (CSF) rhinorrhoea, which can be confirmed by sending the fluid sample for β_2-transferrin assay.

The aim of fracture management is to achieve a 'safe sinus', which means establishing normal sinus function, protecting intracranial structures and preventing short- and long-term complications such as meningitis, Pott's puffy tumour and mucocele. Minimally displaced (<2 mm) fractures of the anterior or posterior table can be managed conservatively with nasal decongestants and long-term observation to exclude complications. The indications for surgical intervention include anterior table disruption with significant forehead deformity, frontonasal duct involvement/obstruction and significant displacement of the posterior table with underlying neurological injury.

Isolated anterior table fractures are usually accessed via a coronal flap; they are reduced and fixed with low-profile titanium miniplates. Posterior table fractures are jointly treated with neurosurgeons and require cranialisation of the frontal sinus with obliteration of the sinus cavity and frontonasal duct. A pericranial flap is placed between the brain and the cranial vault to add an additional barrier against potential postoperative infection. A CT scan at 6 months to 1 year is recommended to ensure that there are no signs of complications.

Summary box 31.9

Frontal sinus fractures

- Frontal sinus fractures may be associated with significant neurological injury because of the significant amount of force directed at the cranium
- The aim of fracture management is to achieve a 'safe sinus'
- Follow-up with a CT scan at 6 months to 1 year is important to exclude long-term complications, which can have severe consequences

Isolated nasal and nasoethmoidal fractures

Isolated nasal bone fractures are common, and the full extent of the deformity may not be apparent for several days after injury. A follow-up appointment 1 week after the initial assessment is important (when the swelling is expected to subside) as it allows for accurate examination. The indications for surgical treatment include a cosmetic defect resulting from deviation and nasal obstruction. Closed reduction with digital manipulation under LA is common, but GA may be required if the nasal bone needs significant disimpaction. A mouldable nasal splint may be utilised to protect the bone reduction from inadvertent force.

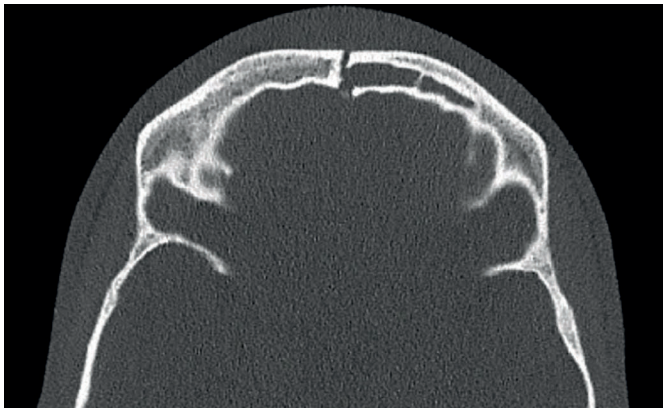

Figure 31.17 An axial CT scan demonstrating a frontal bone fracture through the anterior and posterior table of the frontal sinus.

Nasoethmoidal fractures occur secondary to significant force transfer across the bridge of the nose and the base of the frontal bone. Comminution is common as the nasal and ethmoidal bones are both thin and delicate. The clinical features of nasoethmoidal fractures include periorbital ecchymosis, a depressed nasal bridge, an upturned nasal tip (piggy nose) and telecanthus (increased distance between the inner corners of the eyelids with a normal interpupillary distance), a result of displacement of the bone where the medial canthal ligament is attached. The nasal septum should be inspected for haematoma and a CSF leak excluded.

It is important to identify and treat nasoethmoidal fracture in the primary setting as the untreated fracture can lead to unsightly deformity, which is extremely difficult to correct later. Treatment is often delayed for 7–10 days post injury to allow for the swelling to subside. The key to successful reduction is accurate repositioning of the medial canthus, which can be technically challenging because of the comminuted nature of the fracture.

Summary box 31.10

Nasoethmoidal fractures

- Nasoethmoidal fracture presents with typical features such as a depressed nasal bridge, an upturned nose and telecanthus
- ORIF can be challenging as it requires repositioning of the medial canthal attachment

Panfacial fractures

Combined fractures involving multiple levels such as the mandible, maxilla, zygoma, orbit or frontal bone are described as panfacial fractures. These are some of the most complex of facial injuries and indicate that a significant amount of force

Percival Pott, 1714–1788, surgeon, St Bartholomew's Hospital, London, UK, described the 'puffy tumour' in 1760.

has been applied to the facial skeleton. Panfacial fractures are often associated with severe intracranial, spinal or other organ injuries. Reformatted 3D CT imaging is helpful in demonstrating the full extent and the nature of these fractures (*Figure 31.18*).

Fractures are treated with ORIF once the patient has been stabilised from other significant injuries, and the soft-tissue swelling has sufficiently resolved, usually at a week from injury. The key to panfacial fracture management is in the 'sequencing' of repair, with individual fractures fixed in a similar way to those already described above. The repair of multiple fractures can be difficult because there may be little normal anatomy or intact bony buttresses to act as a guide. Most surgeons experienced in managing this type of injury would tailor the sequence to the particular fracture pattern, optimising the use of normal or near-normal anatomy as a guide.

One of the most common sequencing techniques is a 'top-down' and 'outside-in' approach. This includes first repairing the frontal bone and zygomatic arch fractures followed by orbital rim, nasoethmoidal and mandible fractures. The Le Fort I level maxillary and orbital floor fractures are repaired last. A tracheostomy is often placed because of difficulty with nasal endotracheal intubation and the need to check occlusion during fracture repair, which means oral intubation is not desirable. Alternatively, a submental intubation technique may be one that allows for the occlusion to be checked during fracture repair.

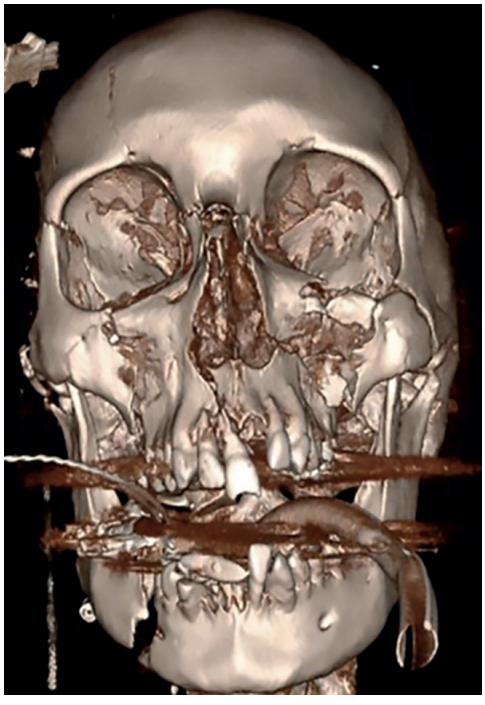

Figure 31.18 A three-dimensional reformatted CT scan demonstrating extensive midface and mandibular fractures (endotracheal and intracranial pressure tubes *in situ*).

Summary box 31.11

Panfacial fractures

- Reformatted 3D CT imaging is very useful in demonstrating the extent and nature of fractures
- Panfacial fracture management requires a 'sequencing' approach, which allows for the fractures to be treated in a systematic way

Dental injuries

The first permanent teeth usually erupt around the age of 6 years; usually lower incisors are followed by upper incisors. Between the ages of 6 and 13, the primary (deciduous) dentition is expected to be exfoliated and replaced by permanent (adult) teeth.

Fractures of the teeth may involve enamel only or enamel in combination with dentine with or without pulp exposure. Exposed dentine and pulp can be exquisitely painful and may benefit from a simple temporary dental dressing.

Avulsed primary teeth should not be reimplanted. Avulsed adult teeth are best reimplanted into the socket immediately after the injury. However, this is generally not possible during prehospital care, and therefore the tooth should ideally be stored in a suitable medium such as milk, saliva or normal saline until expertise is available. The reimplanted tooth needs to be splinted to other teeth with wire and a composite resin material for 2 weeks (sometimes a custom-made splint can be made instead), and the patient treated with antibiotics, chlorhexidine mouthwash and a tetanus vaccine booster as appropriate.

Adult luxated (displaced) teeth mostly require repositing and splinting for 4 weeks. A dentoalveolar fracture (part of the jawbone that includes the teeth) is repositioned and supported with a dental splint for 4 weeks. Luxated primary teeth are generally treated conservatively, or extracted if they are interfering with occlusion.

All dental injuries should be followed up by a dentist for splint removal or monitoring and dental treatment as appropriate.

Summary box 31.12

Dental injuries

- It is important to account for all missing teeth and/or dental fragments – a chest radiograph may be indicated
- An avulsed adult tooth should be reimplanted into the socket as soon as possible or stored in milk, saliva or normal saline
- All dental injuries should be followed up by a dentist

FURTHER READING

Brennan PA, Schliephake H, Ghali GE, Cascarini L. *Maxillofacial surgery*, 3rd edn. London: Elsevier, 2017.

Newlands C, Kerawala C. *Oral and maxillofacial surgery*, 3rd edn. Oxford Specialist Handbooks in Surgery. Oxford: Oxford Medical Publications, 2020.

Perry M, Holmes S. *Atlas of operative maxillofacial trauma surgery: primary repair of facial injuries*. Berlin: Springer, 2014.